

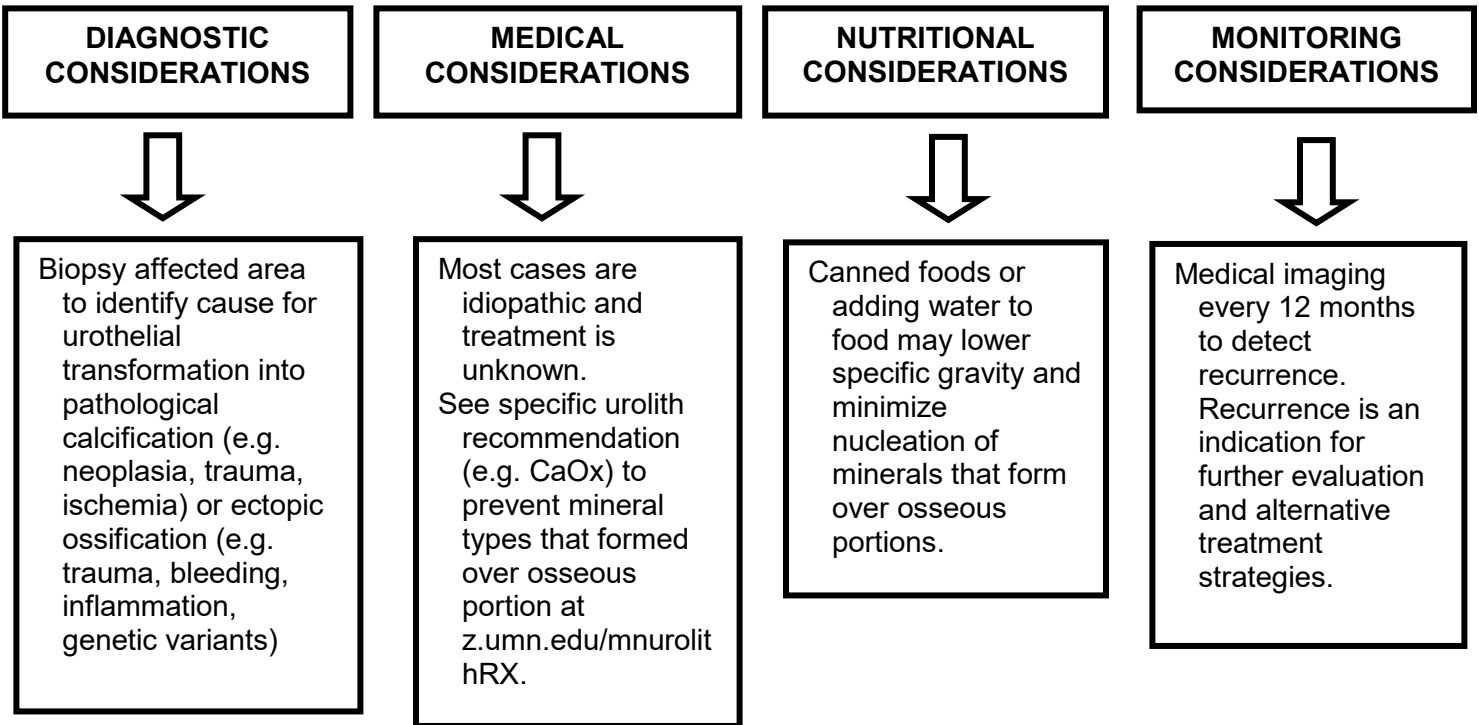


CANINE OSSEOUS

Osseous transformation of the lining of the urinary tract is uncommon. There is little know as to why this occurs and if recurrence is likely.

SEE PUBLICATION: Ectopic Bone as a Nidus for Calcium Oxalate Urocystolithiasis in a Cat, J Vet Intern Med. 31(6):1866–1870

MINIMIZING RECURRENCE



** Review manufacturer’s therapeutic food literature to determine indications/contraindications. For pets with multiple health concerns, consult a veterinary nutritionist to select an optimal food.

Support from [Hills Pet Nutrition](#), veterinarians, and pet owners make our work possible.

